106 Other Vascular Disorders

Robert Kelly and Christopher Baker

Chapter Contents

Livedo Reticularis and Livedo Racemosa 1864
Flushing 1867
Erythromelalgia 1868
Telangiectasias 1870
Venous Lakes 1873
Nevus Anemicus 1873
Angiospastic Macules (Bier Spots) 1874

INTRODUCTION

This chapter will cover several disorders of the skin vasculature, including livedo reticularis, flushing, and erythromelalgia, as well as vascular ectasias such as telangiectasias and venous lakes. Some of the diseases described here are important skin signs of systemic disease, while others are incidental findings. Additional disorders of blood vessels are covered elsewhere, e.g. infantile hemangiomas (Ch. 103), vascular malformations (Ch. 104), and vascular neoplasms and proliferations (Ch. 114).

LIVEDO RETICULARIS AND LIVEDO RACEMOSA

Key features

- Livedo reticularis – may be physiologic or pathologic, presenting as an even and complete reticulated vascular network; due to slow flow and subsequent accumulation of blood within the cutaneous vasculature, with histologic findings that are generally unremarkable
- Livedo racemosa – due to pathologic changes within cutaneous vessels that are identifiable histologically, leading to disruption of cutaneous blood flow; presents as an uneven and fragmented reticular vascular pattern
- Appropriate investigations depend on the clinical context and associated findings

Introduction

The term "livedo" refers solely to a color change, but it is commonly combined with a modifier to describe two different net-like patterns of blanchable, red–purple discoloration. These two types are livedo reticularis (LRe) and livedo racemosa (LRa). LRe is an extremely common finding and usually results from a physiologic vasospastic response to cold exposure. It presents as an even and complete red–purple net-like pattern. Among normal healthy individuals, the predisposition to LRe will vary. However, it can also be a reflection of a number of underlying systemic diseases.

LRa is less common and is associated with underlying pathology. A broken reticular vascular pattern with a disrupted branching appearance is observed. The distribution is often patchy, and depending on the underlying cause and severity, LRa may be accompanied by retiform purpura.

Both LRe and LRa can vary with changes in external temperature, i.e. disappearing with warming and reappearing with cooling. The reticular vascular pattern can become more prominent with rest or it may become less pronounced with exercise or leg elevation due to reduced stasis of blood within cutaneous vessels.

History

The term "livedo reticularis" was first used by Hebra over a century ago to describe a violaceous skin discoloration caused by an abnormality of the cutaneous circulation. Renault (1883) and later Unna (1896) and Spalteholz (1927) suggested that a cone arrangement of the cutaneous microvasculature served as an explanation for the occurrence and pattern of LR[1].

Pathogenesis

Both LRe and LRa result from alterations in blood flow through the cutaneous microvasculature (Fig. 106.1). The latter consists of arterioles that are oriented perpendicularly to the skin surface. The vessels ultimately divide into capillary beds that in turn drain into a subpapillary plexus. It has been proposed that this arrangement of vessels gives rise to a series of 1- to 3-cm cones with the ascending arteriole at the apex of each cone. At the edge of the cone, the venous plexus is more prominent, and the arterial bed is diminished. Any process that either reduces blood flow to and through the skin or reduces drainage of blood out of the skin will result in the accumulation of deoxygenated blood in the venous plexus, leading to the clinical appearance of LRe or LRa[1–3].

There are a number of causes of LRe and LRa (Table 106.1), and the clinical pattern can vary with the nature of the underlying cause.

A complete fine network, as seen in LRe, is indicative of alterations in blood flow caused by vasospasm or by factors within the blood that alter the viscosity and flow through the vessels. On the other hand, vessel wall pathology and intraluminal obstruction can give rise to the irregular, disrupted, patchy pattern of LRa (Figs. 106.2 & 106.3). When LRa is widespread, disorders such as lymphocytic thrombophilic arteritis[4,5], Sneddon syndrome, and antiphospholipid antibody syndrome (APS)[6,7] should be strongly considered.

Clinical Features

Livedo reticularis

Congenital livedo reticularis

Cutis marmorata telangiectatica congenita

Cutis marmorata telangiectatica congenita (CMTC) is characterized by a persistent reticulated vascular pattern that is often limited to one extremity (see Ch. 104), but can be more widespread. Lesions are usually noted at birth, and, when the trunk is involved, there may be a sharp cut-off at the midline. Associated anomalies include other vascular malformations, limb asymmetry, and occasionally neurologic or ocular abnormalities[8,9]. Cutaneous vascular changes can improve during the first few years of life, with 20% of patients showing complete resolution.

Acquired livedo reticularis

Cutis marmorata/physiologic livedo reticularis

These terms are synonymous and refer to a normal pattern of LRe that is due to vasospasm in response to cold (Fig. 106.4A). It is often more marked in neonates, infants, and young children[2,3], with the term *cutis marmorata* often used to describe LRe in children. The LRe is often widespread, particularly on the lower extremities. There is significant fluctuation with changes in temperature, and the vascular pattern generally disappears with warming. Although frequently physiologic in nature, secondary causes such as vasospasm in the setting of lupus erythematosus and Raynaud phenomenon need to be considered (see Table 106.1)[2,3]. In adults, it may be associated with a tendency towards acrocyanosis and chilblains.

Downloaded for Anonymous User (n/a) at Egyptian Knowledge Bank from ClinicalKey.com by Elsevier on March 10, 2024. For personal use only. No other uses without permission. Copyright ©2024. Elsevier Inc. All rights reserved.

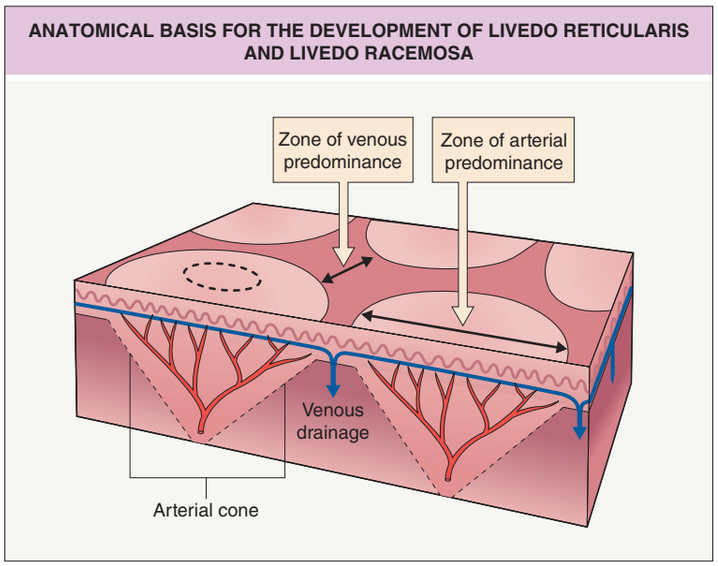

Fig. 106.1 Anatomical basis for the development of livedo reticularis and livedo racemosa. An elliptical biopsy from the paler central "hole" in the net pattern is necessary in order to sample the affected arterioles (dashed oval); serial sectioning may be required.

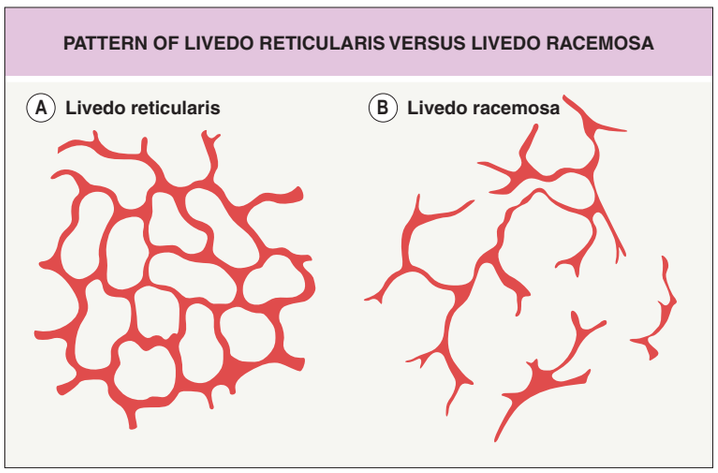

Fig. 106.2 Pattern of livedo reticularis (A) versus livedo racemosa (B).

Fig. 106.3 Livedo racemosa in a patient with lymphocytic thrombophilic arteritis. A more irregular, broken, and branching pattern is seen, as compared to livedo reticularis.

CAUSES OF LIVEDO RETICULARIS AND LIVEDO RACEMOSA
Livedo reticularis
Congenital
• Cutis marmorata telangiectatica congenita
Acquired
Vasospasm
• Cutis marmorata/physiologic livedo reticularis • Autoimmune connective tissue diseases (e.g. SLE) • Raynaud phenomenon/disease
Intraluminal pathology

• Increased normal blood components
  • Thrombocythemia
  • Polycythemia vera
• Abnormal proteins
  • Cryoglobulins
  • Cryofibrinogens
  • Cold agglutinins
  • Other paraproteins (e.g. IgM)

Livedo racemosa
Vessel wall pathology

• Vasculitis
  • Cutaneous polyarteritis nodosa (cutaneous arteritis)
  • Systemic polyarteritis nodosa
  • Cryoglobulinemic vasculitis
  • Autoimmune connective tissue disease-associated vasculitis (e.g. rheumatoid arthritis, SLE, Sjögren syndrome)
• Lymphocytic thrombophilic arteritis (macular arteritis, macular lymphocytic arteritis)
• Calciphylaxis
• Sneddon syndrome
• Deficiency of adenosine deaminase 2
• VEXAS syndrome
• Livedoid vasculopathy (also intraluminal obstruction)

Intraluminal pathology

• Thrombophilia/hypercoagulability (see Table 105.9)
  • Antiphospholipid antibody syndrome
  • Protein S and C deficiencies
  • Antithrombin III deficiency
  • Factor V Leiden mutation
  • Homocystinuria, hyperhomocysteinemia
  • Disseminated intravascular coagulation
  • SARS-CoV-2
• Thrombotic thrombocytopenic purpura
• Embolic
  • Cholesterol emboli
  • Septic emboli
  • Atrial myxoma
  • Nitrogen (decompression sickness)
  • Carbon dioxide arteriography
• Hyperoxaluria/oxalosis
• Intralymphatic histiocytosis

Additional causes of livedo reticularis and livedo racemosa
• Medications (e.g. amantadine, norepinephrine, gemcitabine, interferon) • Infections (e.g. hepatitis C [vasculitis], *Mycoplasma* spp. [cold agglutinins], syphilis) • Neoplasms (e.g. pheochromocytoma) • Neurologic disorders (e.g. complex regional pain syndrome [reflex sympathetic dystrophy], paralysis) • Moyamoya disease

Table 106.1 Causes of livedo reticularis and livedo racemosa. SLE, systemic lupus erythematosus; VEXAS, vacuoles, E1 enzyme, X-linked, autoinflammatory, somatic.

Livedo reticularis due to intraluminal pathology

LRe can result from circulating proteins or cells that slow intravascular blood flow. Abnormal circulating proteins (e.g. cryoglobulins[10], cryofibrinogens, cold agglutinins, IgM paraproteins) can lead to increased blood viscosity. Additionally, an increase in normal blood components in disorders such as polycythemia vera[11] and thrombocythemia

Downloaded for Anonymous User (n/a) at Egyptian Knowledge Bank from ClinicalKey.com by Elsevier on March 10, 2024. For personal use only. No other uses without permission. Copyright ©2024. Elsevier Inc. All rights reserved.

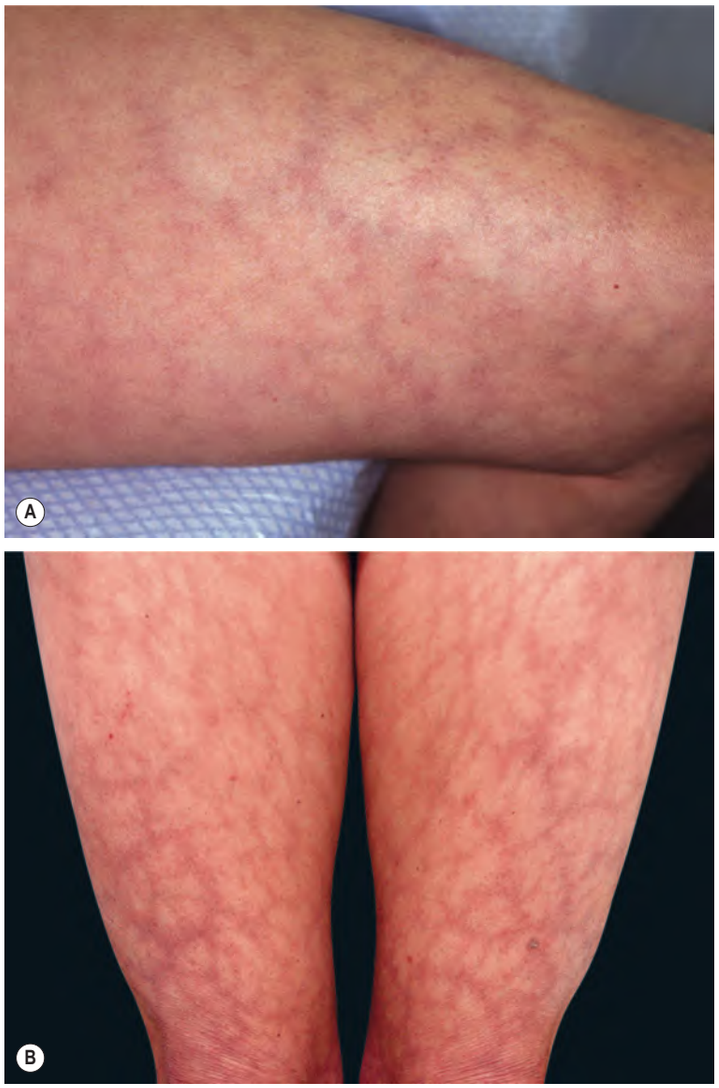

Fig. 106.4 Livedo reticularis. A An even, net-like pattern is seen on the thigh in physiologic livedo reticularis. **B** Livedo reticularis in a patient with systemic lupus erythematosus. *B, Courtesy Jeffrey P. Callen, MD.*

Fig. 106.5 Calciphylaxis in a patient with end-stage chronic renal disease. There is retiform purpura and a large black eschar overlying cutaneous necrosis. Note the violaceous reticulated pattern on the inner thighs. Because the patient was also receiving warfarin, the differential diagnosis included warfarin necrosis. *Courtesy Alicia Little, MD.*

(essential thrombocytosis) may result in altered blood flow. LRe of the lower extremities is often seen in patients with neurologic conditions that lead to immobility of the lower limbs and intravascular stasis.

Livedo racemosa

Livedo racemosa due to vessel wall pathology

LRa results from more significant disruption of blood flow, either from narrowing or complete obstruction of vessel lumina. The most common cause is *vasculitis* involving the medium-sized arterioles at the dermal–subcutaneous junction or in the deep dermis. It is a characteristic finding in cutaneous polyarteritis nodosa (cPAN; more recently renamed cutaneous arteritis)[12], in which there is predominantly involvement of medium-sized arterioles, but can also be seen in systemic PAN and ANCA-associated vasculitides (see Ch. 24). In cPAN, the LRa often has a "starburst" pattern with scattered separate reticulated red–purple patches.

Lymphocytic thrombophilic arteritis, also known as macular arteritis or macular lymphocytic arteritis, often presents with widespread blanchable LRa (see Fig. 106.3)[4,5,13]. Additional clinical findings include patches of macular pigmentation and focal areas of cutaneous ulceration[4]. The vascular inflammation is lymphocytic rather than neutrophilic, and this allows distinction from cPAN. *Livedoid vasculopathy* may also be associated with LRa, but the vascular pattern is usually limited to the lower extremities (see Ch. 23)[14].

Sneddon syndrome is rare and is characterized by widespread LRa as well as multiple transient cerebral ischemic attacks and infarctions. The latter can lead to progressive neurologic impairment[6,7] (see Ch. 23). The LRa is often located on the trunk, buttocks, and proximal extremities, with a typically large branching pattern. Histologically, there is vessel wall thickening due to intimal smooth muscle proliferation and luminal narrowing. Because this thickening can be preceded by partial or complete vessel occlusion by fibrin thrombi, there is overlap with intraluminal pathology (see below).

ADA2 deficiency is due to homozygous or compound heterozygous mutations in *CECR1* which encodes adenosine deaminase 2 (see Ch. 45). This disorder is also known as vasculitis, autoinflammation, immunodeficiency, and hematologic defects syndrome (VAIHS). It usually presents during childhood and the vascular inflammation favors the skin and central nervous system; a PAN-like presentation with LRa and nodules is accompanied by early-onset cerebrovascular accidents (CVAs; see Fig. 45.11). In addition to hepatosplenomegaly, patients may have fevers, hypogammaglobulinemia, and cytopenias[15,16].

Calciphylaxis consists of calcium deposition within the walls of blood vessels (see Ch. 50). It is most commonly seen in the setting of end-stage chronic kidney disease complicated by secondary hyperparathyroidism. Calciphylaxis may initially commence with LRa that then becomes purpuric and subsequently necrotic (Fig. 106.5)[17].

Livedo racemosa due to intraluminal pathology

Complete obstruction of the vessel lumen can result from either emboli (e.g. cholesterol emboli derived from atheromata[18]) or thromboses within vessels due to thrombophilia (hypercoagulability). As outlined in Table 105.9, causes of thrombophilia include APS[19] and deficiencies of protein C[20], protein S, or antithrombin III[21]. Exposure to either heparin or warfarin can also lead to thrombosis-induced cutaneous necrosis. In patients with severe SARS-CoV-2 infection, a thrombotic vasculopathy can develop, with both LRe and LRa having been observed[22].

Intracellular crystal deposition is seen in hyperoxaluria and this also gives rise to luminal obstruction and LRa[23]. A patchy, discontinuous pattern is seen and it may subsequently become purpuric with areas of infarction and necrosis.

Other causes of livedo reticularis and livedo racemosa

There are numerous causes of LRe and LRa cited in the literature, and for most, one of the above mechanisms can generally be implicated. The other causes include drugs such as amantadine[24] and norepinephrine (noradrenaline), as well as infections. The latter can lead to: the production of cryoglobulins, cold agglutinins, or antiphospholipid antibodies; the induction of immune vasculitis; or septic vasculitis or septic emboli. Neoplasms may also be an underlying trigger via hypercoagulability or paraproteinemia as well as vasospasm (e.g. pheochromocytoma). Lastly, these vascular patterns may be seen in several neurologic conditions (e.g. complex regional pain syndrome) as a result of vasospasm or vasodilation (this is in addition to stasis arising from immobility).

Downloaded for Anonymous User (n/a) at Egyptian Knowledge Bank from ClinicalKey.com by Elsevier on March 10, 2024. For personal use only. No other uses without permission. Copyright ©2024. Elsevier Inc. All rights reserved.

Differential Diagnosis

Erythema ab igne is a heat-induced skin disease that begins as a reversible LRe, then with continued heat exposure, it evolves into a fixed reticulated hyperpigmentation. The sites of involvement reflect the source of exposure, e.g. heating pad, laptop computer, space heater. Various cutaneous eruptions may have a reticulated pattern and might be considered in the differential diagnosis, including reticulated erythematous mucinosis (favors mid central trunk) and some viral exanthems (e.g. erythema infectiosum). Poikilodermatous conditions may also have a reticulated pattern (e.g. dermatomyositis, mycosis fungoides); however, the presence of epidermal changes and telangiectasias help to distinguish these conditions.

Pathology

The histology of LRe and LRa varies depending on the underlying cause. In general, no specific abnormality is evident in LRe, but there may be ectasia of superficial blood vessels. With LRa, a number of abnormalities may be seen, including vasculitis, calcium deposition within vessel walls (calciphylaxis; see Fig. 50.6), intravascular eosinophilic plugging (monoclonal cryoglobulinemia; see Fig. 23.4), intraluminal thromboses (hypercoagulable states), cholesterol clefting (cholesterol emboli; see Fig. 23.5), and crystal deposition (oxalosis). In Sneddon syndrome, an occlusive vasculopathy is followed by subendothelial smooth muscle hyperplasia with partial or complete occlusion of affected arterioles. However, in order to find these histopathologic changes, it is necessary to sample the affected arterioles. An elliptical incisional biopsy from the paler central "hole" in the net pattern is necessary and serial sectioning may be required (see Fig. 106.1).

Treatment

Identification of the underlying cause or associated disorder determines the appropriate treatment options.

FLUSHING

Key features

- Flushing is a physiologic response, but in an exaggerated form causes clinical symptoms
- Common triggers (e.g. heat, emotion, exercise, some foods) will exacerbate flushing of any cause
- Causes of excessive flushing include exogenous medications, menopause, neurologic disorders, and systemic diseases (e.g. carcinoid syndrome)

Introduction

Flushing is the term used to describe transient and episodic reddening of the skin, most commonly of the face, and less often the neck, ears, and upper chest. It is the visible sign of a generalized increase in cutaneous blood flow. The greater visibility and capacitance of the superficial cutaneous vasculature of the face and adjacent areas accounts for the limited distribution[25]. In the evaluation of an affected patient, there are a number of causes to consider, including underlying systemic disorders (Table 106.2).

CAUSES OF FLUSHING
• Physiologic
• Exogenous agents (see Table 106.3)
• Menopause
• Neurologic disorders
◦ Anxiety
◦ Autonomic dysfunction, including CNS-driven*
◦ Tumors (e.g. hypogonadal pituitary tumors)
◦ Migraine
◦ Frey syndrome (auriculotemporal syndrome)
• Dumping syndrome due to rapid gastric emptying
• Systemic diseases
◦ Carcinoid syndrome
◦ Mastocytosis
◦ Pheochromocytoma
◦ Medullary carcinoma of the thyroid
◦ Thyrotoxicosis
◦ POEMS syndrome
◦ Pancreatic tumors (e.g. VIPomas)
◦ Prostaglandin-secreting renal cell carcinoma
*May be rapidly fluctuating in the setting of increased intracranial pressure, head trauma, or benzodiazepine withdrawal-induced catatonia.

Table 106.2 Causes of flushing. Rosacea may be associated with pronounced flushing, but usually fixed erythema, papulopustules, edema, and/or telangiectasia are present to some degree. Patients with rubeosis facei diabeticorum may note facial warmth. CNS, central nervous system; POEMS, *p*olyneuropathy, *o*rganomegaly, *e*ndocrinopathy, *M*-protein (monoclonal gammopathy), *s*kin changes; VIP, vasoactive intestinal polypeptide.

EXOGENOUS AGENTS THAT CAN CAUSE FLUSHING
• Alcohol
• Drugs
◦ Angiotensin-converting enzyme (ACE) inhibitors
◦ Calcium channel blockers
◦ Calcitonin
◦ Chlorpropamide*
◦ Cholinergic agonists (e.g. pilocarpine)
◦ Cyclosporine
◦ Dupilumab*
◦ Disulfiram*
◦ Fumaric acid esters
◦ Gold ("nitritoid reactions")
◦ Hormone therapy (e.g. anastrozole, tamoxifen)
◦ Hydralazine
◦ Metronidazole*
◦ Nicotinic acid
◦ Nitrates (e.g. glyceryl trinitrate)
◦ Opiates
◦ Prostaglandins
◦ Sildenafil, tadalafil, vardenafil
◦ Tamoxifen
◦ Topical calcineurin inhibitors*
◦ Serotonin syndrome (usually combination of two drugs such as MAO inhibitor plus SSRI)
• Foods
◦ Spoiled scombroid fish
• Food additives
◦ Monosodium glutamate (MSG), sodium nitrite, sulfites
*With alcohol intake.

Table 106.3 Exogenous agents that can cause flushing. MAO, monoamine oxidase; SSRI, selective serotonin reuptake inhibitor.

Pathogenesis

An increase in cutaneous blood flow occurs with relaxation of vascular smooth muscle. This may occur via the autonomic nervous system[26] (usually leading to active vasodilation), endogenous vasoactive agents (such as histamine and serotonin), or exogenous agents (Table 106.3). Alcohol-induced flushing may result from the direct effect of alcohol as well as cutaneous vasodilation from elevated blood levels of acetaldehyde; the latter occurs in those with alcohol dehydrogenase deficiency (prevalent in East Asians) and in the "disulfiram reaction" induced by some medications. Flushing from fermented alcoholic drinks may be caused by vasoactive substances such as tyramine. Vasodilation mediated by the autonomic nervous system is often accompanied by eccrine sweating due to a direct effect on both sweat glands and blood vessels (wet flush)[27]. Direct vasodilation by vasoactive agents is usually not associated with increased sweating (dry flush).

Clinical Features

Blushing is a common emotionally triggered form of flushing associated with embarrassment and anxiety and is considered an exaggerated physiologic response. *Physiologic flushing* also occurs as part of normal

Downloaded for Anonymous User (n/a) at Egyptian Knowledge Bank from ClinicalKey.com by Elsevier on March 10, 2024. For personal use only. No other uses without permission. Copyright ©2024. Elsevier Inc. All rights reserved.

thermoregulation in response to heat or exercise. *"Hot flashes"* refer to flushing associated with menopause, which lasts for a few minutes and is usually associated with sweating[28].

Flushing of any cause may be exacerbated or triggered by a number of common factors such as heat, hot drinks, exercise, anxiety, food additives (e.g. sulfites), and alcohol. Affected patients often report a feeling of heat and burning of the skin during episodes and find the color change a social hindrance. Some patients become anxious that they will flush at inopportune times and this further exacerbates the problem. Repeated flushing may result in permanent "fixed" erythema and telangiectasias.

Carcinoid tumors that secrete vasoactive agents (e.g. serotonin) are associated with the carcinoid syndrome (Table 106.4). This syndrome includes flushing, which is often severe[29], and it may be precipitated by common triggers of flushing. The classic "carcinoid flush" occurs with ~10% of *midgut* tumors (small intestine, appendix, proximal colon), but only when there are associated liver metastases; it lasts minutes and consists of erythema and pallor as well as a cyanotic hue. Type III *gastric* carcinoid tumors are associated with a pruritic, patchy, bright red flush admixed with white patches and probably mediated by histamine. *Bronchial* tumors are associated with a prolonged (hours to days), intensely red to purple flush. Hindgut tumors (distal colon, rectum) are rarely, if ever, associated with the carcinoid syndrome and flushing, even with liver metastases.

An approach to the clinical assessment of flushing and relevant investigations are listed in Table 106.5.

SIGNS AND SYMPTOMS OF THE CARCINOID SYNDROME
• Cutaneous
• Flushing
• Vascular rosacea-like changes
• Pellagra
• Edema and induration of the face > extremities
• Bronchospasm
• Diarrhea
• Cardiac dysfunction (right-sided)
• Hypotension
• Peptic ulcers

Table 106.4 Signs and symptoms of the carcinoid syndrome.

CLINICAL APPROACH TO THE EVALUATION OF FLUSHING
1. Identify provocative factors
• Direct questioning
• Patient diary (food, medications, activities)
2. Check for associated symptoms
• Sweating
• Fever
• Urticaria
• Diarrhea
• Bronchospasm
3. Investigation (not required in all cases)
Indicated if flushing:
• Of sudden or recent onset
• Severe
• Associated with systemic symptoms
Investigations to consider:
• Complete blood count with differential and platelets
• Thyroid function tests
• Serum estrogen, FSH, LH
• Serum tryptase [M]; serum chromogranin A levels [C]; plasma free metanephrines [P]
• 24-hour urine collection for:
• Serotonin metabolites such as 5-hydroxyindole acetic acid (5-HIAA) [C]
• Fractionated metanephrines (more specific but less sensitive than plasma) [P]
• Histamine metabolites such as methylimidazole acetic acid (MeImAA) [M]
• CT/MRI scans; octreotide/somatostatin receptor scintigraphy (using radiolabeled octreotide)
4. Elimination
• Exclude suspected drugs and food additives

Table 106.5 Clinical approach to the evaluation of flushing. C, carcinoid; FSH, follicle stimulating hormone; LH, luteinizing hormone; M, mastocytosis; P, pheochromocytoma.

Differential Diagnosis

Fixed erythema, and sometimes telangiectasias, of the face and neck are seen in fair-skinned individuals with photodamage as well as patients with seborrheic dermatitis and photosensitive autoimmune connective tissue diseases (e.g. dermatomyositis). Affected individuals may complain of the persistent redness and burning of the skin rather than actual flushing. Rosacea may be associated with pronounced flushing, but usually fixed erythema, papulopustules, edema, and/or telangiectasias are present to some degree.

Treatment

The clinician should consider and eliminate any suspected exogenous cause (see Table 106.3). Underlying systemic causes, although rare, should be considered (see Table 106.2). Triggers of flushing are likely to be clinically relevant in most patients and should be avoided where possible. Non-selective β-blockers (e.g. nadolol, propranolol) or clonidine may be effective in idiopathic flushing. Anxiolytics may be helpful, particularly if emotional symptoms or anxiety are triggers. Menopausal flushing may respond to hormone replacement therapy, clonidine, or selective serotonin reuptake inhibitors (SSRIs). In troublesome cases unresponsive to these measures, transthoracic endoscopic sympathectomy may be considered.

ERYTHROMELALGIA

Synonyms: ▪ Erythermalgia ▪ Erythralgia

Key features

- Characterized by painful burning and erythema of the distal extremities (lower > upper)
- Precipitated by heat and relieved by cooling
- May be idiopathic, familial, or arise secondarily due to an underlying condition (e.g. thrombocythemia)

Introduction

Erythromelalgia is an episodic condition characterized by a burning sensation, erythema, and increased skin temperature. It affects acral sites, particularly the lower extremities. Classically, there are three major forms, including:

- type 1 – associated with thrombocythemia
- type 2 – primary or idiopathic form
- type 3 – associated with underlying causes other than thrombocythemia.

History

The term "erythromelalgia" was first coined by Mitchell in 1878. It was used to describe redness (erythros), involvement of extremities (melos), and pain (algos). The diagnostic criteria were established by Thompson[30] in 1979: (1) burning pain in the extremities; (2) pain aggravated by warming; (3) pain relieved by cooling; (4) erythema of affected skin; and (5) increased temperature of affected skin.

Epidemiology

In Norway, the estimated incidence of erythromelalgia is 0.25/100 000 with a prevalence of 2/100 000[31]. While types 1 and 3 usually appear during adulthood, type 2 may appear in childhood and may be familial. The female : male incidence varies from 2 : 1 to almost 3 : 1. In one study, the mean age of onset was 56 years (range, 5–91 years) with 4% having their symptoms begin during childhood.

Pathogenesis

While the discovery of *SCN9A* mutations in patients with primary familial erythromelalgia has provided insights into this disorder, in general, the pathogenesis of erythromelalgia is not entirely understood. Firstly, it may

Downloaded for Anonymous User (n/a) at Egyptian Knowledge Bank from ClinicalKey.com by Elsevier on March 10, 2024. For personal use only. No other uses without permission. Copyright ©2024. Elsevier Inc. All rights reserved.

vary depending on the underlying cause and between different patient subgroups. For example, in patients with thrombocythemia, the pathophysiology is likely to be related to both increased numbers of platelets as well as abnormalities in platelet function. Of note, one explanation for why type 1 erythromelalgia does not respond to heparin or warfarin is that the microthrombi that form do not require thrombin activation[32].

In other types of erythromelalgia, changes in vascular dynamics may be a factor. It has been proposed that hyperemia results from increased blood flow through arteriovenous shunts with a resultant reduction in blood flow within nutritional vessels, thus leading to cutaneous hypoxia[31,33]. Another proposed mechanism is vasoconstriction (as occurs in Raynaud phenomenon), but in erythromelalgia this is followed by a prolonged phase of hyperemia[34]. A temperature-triggered release of vasoactive substances and chemical pain mediators may also play a role.

In 2004, gain-of-function missense mutations in *SCN9A*, which encodes the voltage-gated sodium channel alpha subunit Nav1.7, were first described in patients with primary familial erythromelalgia[35]. Nav1.7 produces threshold currents and is expressed primarily within dorsal root ganglia of sensory neurons (especially nociceptors) and sympathetic ganglion neurons. Mutations lead to lowered thresholds and "over-excitability" of pain-signaling sensory neurons[36] while at the same time producing "under-excitability" of sympathetic neurons. Certain mutations that produce a lesser effect on sodium channel activation and subsequent neuron excitability are associated with a later onset of clinical signs and symptoms[37].

Another dominantly inherited pain syndrome, paroxysmal extreme pain disorder, has also been found to be due to gain-of-function mutations in *SCN9A*, whereas loss-of-function mutations in both copies of this gene lead to a recessively inherited insensitivity to pain[38]. Lastly, there exist additional families that are not linked to chromosome 2q31–32 (*SCN9A* locus), suggesting genetic heterogeneity[39].

Associations in secondary erythromelalgia include myelodysplastic syndromes, diabetes mellitus, peripheral arterial disease, vasculitis, systemic lupus erythematosus, and other autoimmune connective tissue diseases.

Clinical Features

Erythromelalgia is characterized by burning, erythema, and warmth of acral sites (Fig. 106.6). Attacks most commonly occur late in the day, last through the night, and frequently impair sleep. The symptoms are usually episodic, although occasionally they may be continuous. The feet are involved in 90% of patients, whereas the hands are affected in 25%. Less commonly, there is also involvement of the head and neck. Type 1 erythromelalgia may be unilateral and is more frequently associated with progression to ischemic necrosis. In contrast, the idiopathic form is more likely to be bilateral. The pain is precipitated by minor elevations in temperature (between 32°C and 36°C). Other exacerbating factors include exercise, standing, walking, fever, and limb dependency. Cooling and limb elevation generally reduce the symptoms.

The affected areas will often appear red and swollen. Other findings include acrocyanosis, livedo reticularis, facial flushing, cutaneous necrosis, and ulceration. In up to 40% of patients, the limb may appear normal between attacks. Prolonged immersion in water can lead to extensive maceration and contribute to ulcer formation.

Prognosis is variable. In one long-term study, ~30% of patients fell into each of three categories: worsening, no change, and improvement. A further 10% had complete resolution of their symptoms[40].

Pathology

In type 1 erythromelalgia, vessels may show intimal proliferation and occlusive thrombosis followed by complete fibrosis of the affected arterioles. In general, however, biopsies are not required and histology is nonspecific.

Differential Diagnosis

Complex regional pain syndrome (CRPS; reflex sympathetic dystrophy) may sometimes have features similar to erythromelalgia (see Ch. 6). Abnormal warmth, erythema, and burning pain may be seen in both, but CRPS does not have the characteristic close relationship to temperature and tends to be constant rather than episodic. Peripheral neuropathy may also cause tingling and burning and may require differentiation by nerve conduction studies. Calcium channel blockers, autonomic dysfunction, acrodynia, and mushroom poisoning, as well as occlusive vascular diseases such as thromboangiitis obliterans, may be associated with erythromelalgia-like symptoms. It is important to consider underlying causes of erythromelalgia – in particular, chronic myeloproliferative disorders – as erythromelalgia may be the first sign of the latter.

Treatment

Although numerous treatments have been reported as possible therapies for erythromelalgia, no single therapy is consistently effective and many cases can prove difficult to control. The assistance of a specialist pain clinic can be valuable. Various methods of cooling the limbs during attacks, such as fans, wet dressings, and ice packs wrapped in towels, should be explored and have often already been tried by the time of presentation. Frequent periods of leg elevation can be helpful in reducing both discomfort and leg edema, whereas prolonged periods of leg dependency should be avoided. Simple oral analgesia is also important.

Aspirin can be effective for type 1 erythromelalgia and treatment for the thrombocythemia with medications such as hydroxyurea and (based upon mutational analysis) JAK inhibitors should also be considered. Topical therapies include capsaicin cream, 1%–2% amitriptyline/0.5% ketamine gel, and lidocaine patches, while possible oral medications include SSRIs (e.g. venlafaxine), tricyclic antidepressants (e.g. amitriptyline), anticonvulsants (e.g. gabapentin, carbamazepine), calcium channel blockers (e.g. diltiazem), the prostaglandin analogue misoprostol, and especially

Fig. 106.6 Erythromelalgia. Red hot painful hand (**A**) and feet (**B**) in two patients with erythromelalgia. *A, Courtesy Agustin Aloma, MD.*

Downloaded for Anonymous User (n/a) at Egyptian Knowledge Bank from ClinicalKey.com by Elsevier on March 10, 2024. For personal use only. No other uses without permission. Copyright ©2024. Elsevier Inc. All rights reserved.

in primary inherited erythromelalgia, sodium channel blocking agents (e.g. mexiletine, flecainide)[41,42]. With the report of functional expression studies (based upon a specific mutation) correlating with clinical responsiveness to carbamazepine or mexiletine, the possibility exists of utilizing such assays in the future to guide therapy. Rizatriptan, a selective agonist of serotonin 5-HT_{1B} and 5-HT_{1D} receptors, can be used for acute pain attacks in patients with primary erythromelalgia. In addition, there are ongoing trials of Nav1.7 channel blockers, both oral and topical.

Several intravenous therapies have been used for more severe cases, including nitroprusside, prostaglandin E1, and lidocaine (combined with oral mexiletine). More invasive approaches include epidural infusions of bupivacaine and opiates, lumbar sympathetic blocks, and bilateral lumbar sympathectomies[43]. Oral medications should be tried initially, but more invasive procedures may be necessary for more severe cases.

TELANGIECTASIAS

Key features

- Telangiectasia is due to persistently dilated dermal vessels and not angiogenesis
- Can occur as a primary process, a result of cutaneous damage, or secondary to systemic disease

Introduction

Telangiectasia refers to abnormal, small, persistently dilated blood vessels visible in the skin (Fig. 106.7). Individual vessels can be discerned and range in color from light red to deep purple and will usually empty with pressure. They occur as a result of vascular dilation rather than new vessel growth and are thought to arise from capillaries, venules, or small arteriovenous malformations. Telangiectasias are seen in a range of clinical settings (Table 106.6).

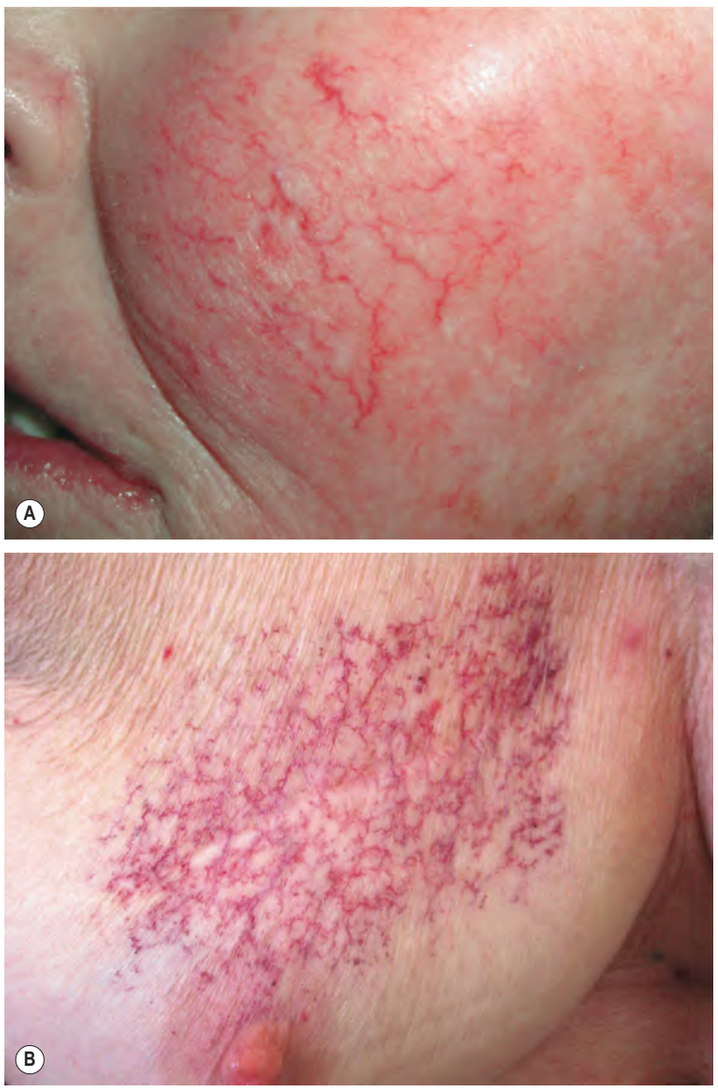

Fig. 106.7 Telangiectasias. A Sun-induced telangiectasias on the cheek. **B** Prominent telangiectasias on the breast following radiation therapy.

CAUSES OF TELANGIECTASIAS
Primary
• Spider telangiectasias (also associated with estrogen excess)
• Hereditary benign telangiectasia (Fig. 106.8)*
• Costal fringe
• Angioma serpiginosum
• Unilateral nevoid telangiectasia
• Generalized essential telangiectasia
• Cutaneous collagenous vasculopathy
Secondary to physical changes or damage
• Photodamage
• Post radiation therapy
• Traumatic
• Venous hypertension
Skin disease
• Telangiectatic rosacea
• Incipient or involuted infantile hemangiomas
• Basal cell carcinoma
Hormonal/metabolic
• Estrogen-related
◦ Liver disease
◦ Pregnancy
◦ Exogenous estrogens
• Corticosteroids (topical, systemic, Cushing syndrome)
Anti-neoplastic agents
• Tesirine† (e.g. loncastuximab tesirine-lpyl)
• Ado-trastuzumab emtansine†
Systemic conditions
• Carcinoid syndrome
• Mastocytosis (telangiectasia macularis eruptiva perstans)
• Autoimmune connective tissue diseases
◦ Lupus erythematosus
◦ Dermatomyositis
◦ CREST syndrome/systemic sclerosis
• Mycosis fungoides, including poikilodermatous
• B cell lymphomas
• TEMPI syndrome
• Angiolupoid sarcoidosis
• GVHD (in the context of poikiloderma)
• HIV infection (anterior chest)
Congenital malformations and genodermatoses
• Cutis marmorata telangiectatica congenita
• Klippel–Trenaunay syndrome
• Hereditary hemorrhagic telangiectasia
• Ataxia–telangiectasia
• Hypotrichosis–lymphedema–telangiectasia syndrome
• Rombo syndrome
• Bloom syndrome
• Rothmund–Thomson syndrome
• Poikiloderma with neutropenia
• Dyskeratosis congenita
• Xeroderma pigmentosum
• Goltz syndrome (in lines of Blaschko)
• GM1-gangliosidosis (also associated with angiokeratoma corporis diffusum)
• Prolidase deficiency
*Childhood onset of multiple punctate, linear, or arborizing telangiectasias favoring sun-exposed areas of the face and upper extremities; the vermilion lips and palate are occasionally affected, but there is no visceral involvement. †Cytotoxic payload in monoclonal antibody drug conjugates.

Table 106.6 Causes of telangiectasias. GVHD, graft-versus-host disease; TEMPI, telangiectasias, elevated erythropoietin and erythrocytosis, monoclonal gammopathy, perinephric fluid collections, and intrapulmonary shunting.

Downloaded for Anonymous User (n/a) at Egyptian Knowledge Bank from ClinicalKey.com by Elsevier on March 10, 2024. For personal use only. No other uses without permission. Copyright ©2024. Elsevier Inc. All rights reserved.

Fig. 106.8 Hereditary benign telangiectasia. Fine linear and branching telangiectasias are seen on the cheeks bilaterally in this five-year-old boy. There is no associated visceral involvement. *Courtesy Julie V. Schaffer, MD.*

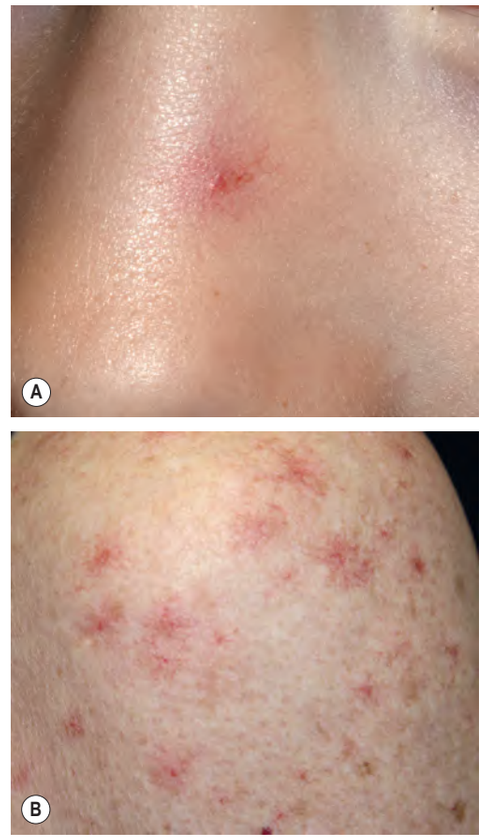

Fig. 106.9 Spider telangiectasia. They are characterized by a central arteriole with radiating telangiectatic "legs". **A** Single lesion on the nose of a young child. **B** Multiple lesions on the shoulder of an adult with liver disease. *A, Courtesy Julie V. Schaffer, MD; B, Courtesy Jeffrey P. Callen, MD.*

Treatment is often not required; however, options include cosmetic camouflage, light or fine wire diathermy, injection sclerotherapy, and laser or intense pulsed light therapies.

Spider Telangiectasia

Synonyms: ▪ Nevus araneus ▪ Spider nevus ▪ Spider angioma

This localized lesion has a slightly raised central red papule (which often becomes more prominent with time) and multiple small, radiating, dilated vessels ("legs")[44] (Fig. 106.9). The lesion can vary from several millimeters to more than a centimeter in diameter. They are commonly located on the face, neck, upper trunk, and hands.

Spider telangiectasias represent a form of telangiectasia with a central feeding arterial vessel. They are usually seen in otherwise healthy individuals, especially women and children. Lesions, often multiple, commonly occur with pregnancy, liver disease, and oral contraceptive pills (OCPs). Spontaneous resolution may occur, especially after pregnancy. Treatment options include electrosurgery or vascular lasers.

Generalized Essential Telangiectasia

This is a primary disorder that typically affects adult women but may commence during childhood. Initially, the limbs are affected, especially the distal lower extremities, with sheets of asymptomatic blanchable telangiectasias (Fig. 106.10)[45,46]. The involvement is usually symmetric. Over time, there is often a progression proximally such that the telangiectasias become more widespread. Although the telangiectasias are persistent, patients do not have associated systemic illnesses.

The differential diagnosis includes cutaneous collagenous vasculopathy; typically it is not confused with telangiectasia macularis eruptiva perstans. While improvement with vascular lasers is possible, the progressive nature must be considered and the cost of treating extensive involvement may prove prohibitive.

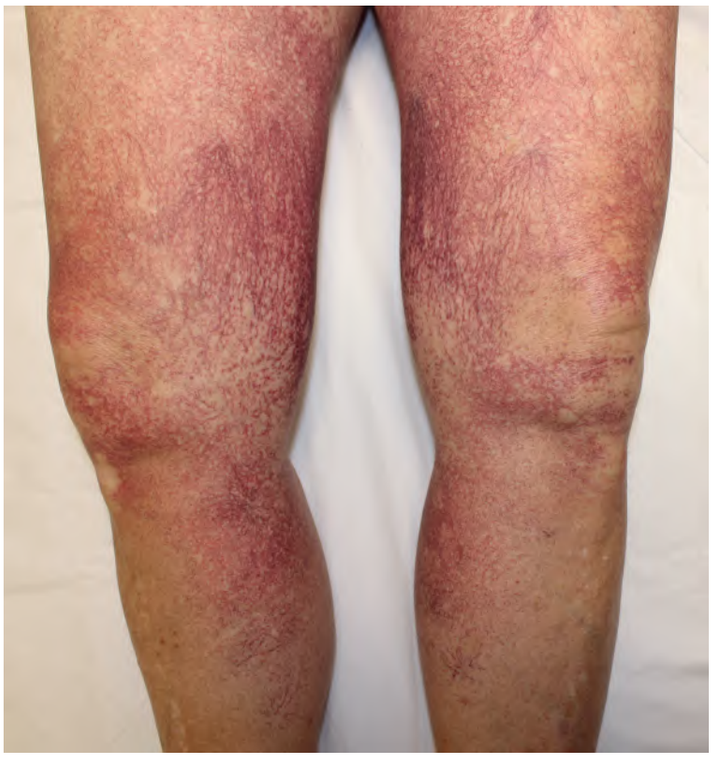

Fig. 106.10 Generalized essential telangiectasia. Bilateral sheets of asymptomatic blanchable telangiectasias. The initial site of involvement is usually the distal lower extremity. *Courtesy Jean L. Bolognia, MD.*

Cutaneous Collagenous Vasculopathy

Cutaneous collagenous vasculopathy (CCV) was first described in 2000[47]. Clinically, it can resemble generalized essential telangiectasia (GET). However, based upon the limited number of reported cases, there is not a female predominance, the telangiectasias may involve just the trunk and/or proximal extremities, and history of an "upward march" of lesions is lacking (Fig. 106.11A)[48]. The etiology is unknown and there is no clear association with any underlying systemic illness or medication.

Downloaded for Anonymous User (n/a) at Egyptian Knowledge Bank from ClinicalKey.com by Elsevier on March 10, 2024. For personal use only. No other uses without permission. Copyright ©2024. Elsevier Inc. All rights reserved.

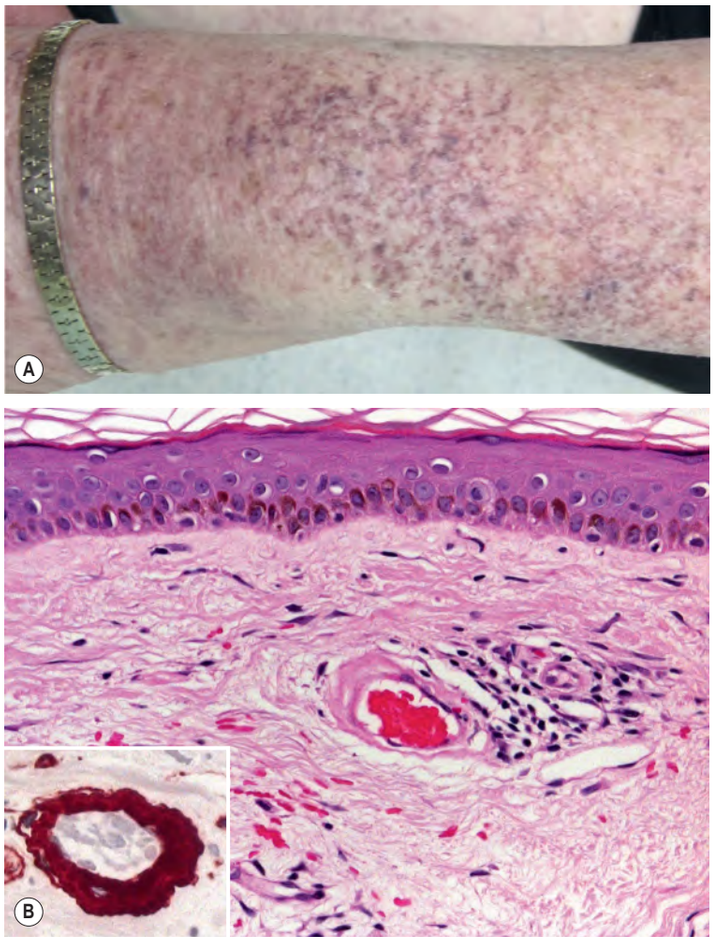

Fig. 106.11 Cutaneous collagenous vasculopathy – clinical and histologic features. A Multiple violaceous branching telangiectasias on the forearm; the patient also had involvement of the thighs, abdomen, and back. **B** In the upper dermis, there are some extravasated red blood cells and clumped RBCs within an ectatic blood vessel. Note the concentric hyaline deposits at the periphery of the affected blood vessel. Immunohistochemical staining with antibodies to collagen type IV highlight the deposits (inset). *B, Courtesy Lorenzo Cerrroni, MD.*

Fig. 106.12 Unilateral nevoid telangiectasia. Note the segmental, unilateral distribution pattern of discrete telangiectasias. *Courtesy Robert Hartman, MD.*

Fig. 106.13 Angioma serpiginosum. Grouped dark red puncta on the arm in a serpiginous pattern.

CCV does have unique histopathologic findings consisting of ectatic superficial blood vessels with hyalinized and laminated, concentric concretions surrounding the basement membrane of affected vessels. With special staining, this material is PAS-positive and diastase-resistant, and by immunohistochemistry, it reacts with antibodies against collagen type IV (Fig. 106.11B). Ultrastructurally, the deposits have been shown to consist of collagen with abnormal banding patterns (Luse bodies)[48].

This condition, like generalized essential telangiectasia, is benign in nature. There are scattered case reports of improvement following pulsed dye laser therapy.

Unilateral Nevoid Telangiectasia

Telangiectasias in this condition are usually confined to the trigeminal or upper cervical dermatomes (Fig. 106.12) and may follow the lines of Blaschko[49,50]. Congenital and acquired forms are recognized. It has been proposed that an increase in estrogen receptors on blood vessels in affected areas and/or an increase in estrogen levels is causative. Situations of relative estrogen excess such as pregnancy, puberty, and liver disease are associated with the acquired form.

Angioma Serpiginosum

Angioma serpiginosum is a rare vascular disorder with a characteristic appearance[51,52]. It is usually sporadic, but familial cases have been reported. Typically, the condition affects female patients and commences during the first two decades of life. Multiple, small, asymptomatic, non-palpable, deep-red to purple puncta occur in small clusters and sheets (Fig. 106.13). The arrangement and extension of the lesions may produce a serpiginous pattern. The extremities are most commonly affected, initially with a unilateral distribution; over months to years, the involvement may become more widespread. The palms, soles, and mucous membranes are not involved.

The puncta represent dilated, non-inflamed capillaries within the dermal papillae. These can be seen with dermoscopy. Incomplete blanching occurs with pressure, but lesions are not purpuric. The differential diagnosis includes pigmented purpuric eruptions, particularly the Majocchi variant (purpura annularis telangiectoides), which is more likely to be bilateral and on biopsy has perivascular lymphocytes and extravasated erythrocytes. Treatment is not necessary, but lesions can be improved with the pulsed dye laser.

Hereditary Hemorrhagic Telangiectasia

Synonyms: ▪ Osler–Weber–Rendu disease ▪ Osler–Rendu–Weber disease

Hereditary hemorrhagic telangiectasia (HHT) is an autosomal dominant condition in which there are multiple mucocutaneous and gastrointestinal telangiectasias (which are actually arteriovenous malformations)

Downloaded for Anonymous User (n/a) at Egyptian Knowledge Bank from ClinicalKey.com by Elsevier on March 10, 2024. For personal use only. No other uses without permission. Copyright ©2024. Elsevier Inc. All rights reserved.

as well as variable visceral involvement (lung, liver, and CNS). The diagnosis may first be suspected in children who have repeated episodes of epistaxis; however, the initial presentation can occur during the second or third decades of life. The characteristic mat-like and papular telangiectasias on the mucous membranes are first seen during adolescence[53]. Cutaneous lesions usually appear after puberty or even later in life.

Lesions, which increase in size and number as the patient ages, are most commonly seen on the face, tongue, lips, nasal mucosa, hands, and fingertips (Fig. 106.14). They frequently occur throughout the gastrointestinal tract and may result in obvious hemorrhage or iron deficiency anemia. Hemorrhage from vascular lesions in the lung, liver, CNS, spleen, and urinary tract may occur, as well as paradoxical emboli due to pulmonary arteriovenous malformations.

HHT can result from mutations in several genes, most commonly *HHT1* and *HHT2* which encode endoglin and ALK-1, respectively (see Table 104.2). Both of these glycoproteins are TGF-β receptors expressed by vascular endothelium, and they are thought to play a role in angiogenesis and vessel wall integrity.

Treatment of the mucocutaneous vascular lesions may not be required. Destructive treatments such as diathermy, cautery, or laser may be used to treat individual lesions. Surgical management or embolization may be required for uncontrolled hemorrhage from mucosal lesions or complications arising from visceral lesions. Initial and longitudinal evaluation of patients with HHT is outlined in Table 104.6.

Ataxia–Telangiectasia

Synonym: ▪ Louis-Bar syndrome

Ataxia–telangiectasia was first described by Louis-Bar in 1941. It is an autosomal recessive disorder characterized by cerebellar ataxia, chromosomal instability (frequent translocations between chromosomes 7 and 14), growth retardation, oculocutaneous telangiectasias, pulmonary infections (including bronchiectasis), immunodeficiency, and the development of lymphomas[54].

It is covered in more detail in Chapter 60. Linear telangiectasias first appear on the bulbar conjunctivae between 4 and 6 years of age. Cutaneous telangiectasias favor the head and neck region, and they are most common on the malar prominences, ears, and eyelids in addition to the popliteal and antecubital fossae. Patients may have poikiloderma (hypopigmentation, hyperpigmentation, atrophy, telangiectasia), premature hair graying, and decreased subcutaneous fat.

VENOUS LAKES

Venous lakes are small, dark-blue, slightly elevated, soft lesions that are predominantly localized on the lips (Fig. 106.15), ears, or face of older adults. They can usually be emptied of most of their blood content by persistent pressure[55,56]. Pathologically, venous lakes represent telangiectasias in the dermis. Either one great, dilated venule or several communicating dilated spaces that contain erythrocytes are seen. Thrombosis is sometimes present. Optional treatment with electrosurgery or a hemoglobin-targeting laser is usually effective.

NEVUS ANEMICUS

Nevus anemicus is a congenital pale area of skin, most commonly found on the upper to mid trunk. These patches have an irregular border and an average diameter of 5–10 cm (Fig. 106.16). Within the body of the lesion, local blood vessels are very sensitive to endogenous catecholamines and are permanently vasoconstricted[57]. The border and extent of the lesion become imperceptible with pressure (or diascopy) sufficient to cause blanching of surrounding skin. Conversely, application of heat or an ice cube will often accentuate the lesion; the border becomes hyperemic during warming, while the lesion stays pale. The pale appearance of the lesion (rather than an absence of pigmentation) and the results of the above clinical maneuvers allow nevus anemicus to be differentiated from vitiligo and nevus depigmentosus, respectively. Interestingly, islands of sparing may be present within the lesion, and skin transplanted within the nevus anemicus retains the characteristics

Fig. 106.15 Venous lake on the lip. The lesion is soft and, with compression, can be emptied of most of its blood content. *Courtesy Ronald P. Rapini, MD.*

Fig. 106.14 Hereditary hemorrhagic telangiectasia. The tongue and lips are a common location for the mat-like and papular telangiectasias that actually represent small arteriovenous malformations.

Fig. 106.16 Nevus anemicus. Pale area of vasoconstriction with irregular borders on the back.

Downloaded for Anonymous User (n/a) at Egyptian Knowledge Bank from ClinicalKey.com by Elsevier on March 10, 2024. For personal use only. No other uses without permission. Copyright ©2024. Elsevier Inc. All rights reserved.

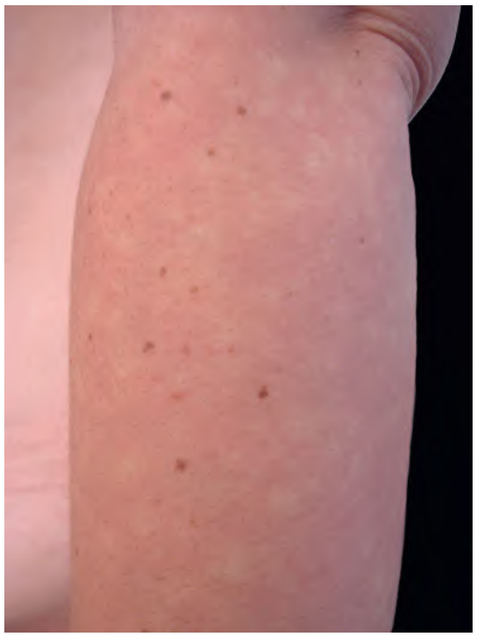

Fig. 106.17 Angiospastic macules (Bier spots). Multiple pale spots with an erythematous background on the forearm.

of the donor site (donor dominance). No histologic abnormalities have been reported. No treatment is required or effective. Of note, nevus anemicus can co-exist with vascular malformations and is seen in up to half of patients with neurofibromatosis type 1.

ANGIOSPASTIC MACULES (BIER SPOTS)

These were first described by Bier in 1898 and represent a pattern of vascular mottling consisting of white macular areas surrounded by a red to occasionally blue cyanotic background. Bier spots most commonly occur on the arms and legs of young adults (Fig. 106.17), but may also occur on the trunk. They are more noticeable in patients with lightly pigmented skin. Angiospastic macules may be induced by venous congestion and can be elicited by placing a limb in a dependent position or by placing a tourniquet around a limb. The spots disappear with limb elevation or release of the tourniquet. As with nevus anemicus, the border of the lesion becomes imperceptible with pressure (diascopy). The vascular pattern is thought to result from a benign physiological response consisting of vasoconstriction. Bier spots have also been associated with pregnancy, lymphedema, cryoglobulinemia, capillary malformation-arteriovenous malformation syndrome (especially type 2 due to *EPHB4* mutations), tuberous sclerosis complex, and aortic hypoplasia. *BASCULE* syndrome features *B*ier *a*nemic *s*pots, *c*yanosis (acral), and an *u*rticaria-*l*ike *e*ruption in association with orthostatic intolerance.

Additional figures available in our eBook (see inside front cover for

eFig. 106.1 Sneddon syndrome. The characteristic irregular, broken, branching pattern of livedo racemosa is seen on the back and arms. *Courtesy Norbert Sepp, MD*.

eFig. 106.3 Livedo racemosa in a patient with lymphocytic thrombophilic arteritis.

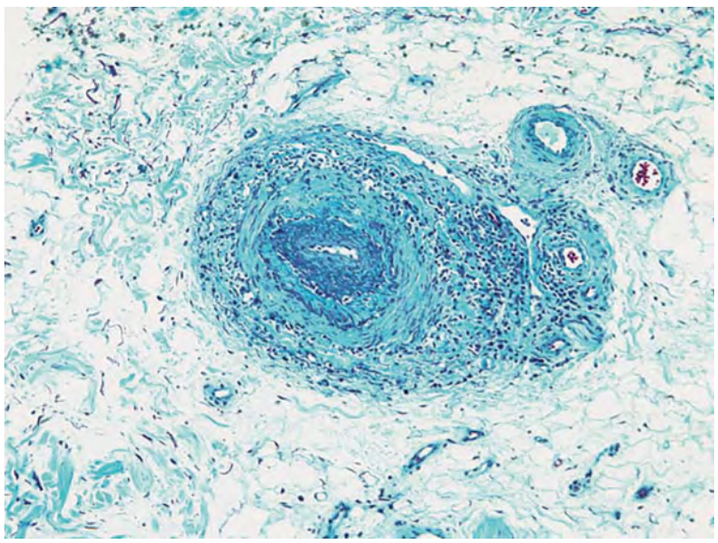

eFig. 106.2 Sneddon syndrome. A connective tissue stain highlights a subcutaneous artery with subendothelial proliferation of smooth muscle, leading to almost complete luminal occlusion.

eFig. 106.4 Reticulate purpura and cutaneous necrosis due to calciphylaxis. These patients also often have patchy areas of livedo reticularis. *Courtesy Norbert Sepp, MD*.

Downloaded for Anonymous User (n/a) at Egyptian Knowledge Bank from ClinicalKey.com by Elsevier on March 10, 2024. For personal use only. No other uses without permission. Copyright ©2024. Elsevier Inc. All rights reserved.

eFig. 106.5 Hereditary benign telangiectasia. Fine linear and punctate telangiectasias are seen on the cheeks and vermilion lips bilaterally in this child. There is no associated visceral involvement. *Courtesy Antonio Torrelo, MD*.

eFig. 106.7 Generalized essential telangiectasia. Bilateral sheets of asymptomatic blanchable telangiectasias. The initial site of involvement is usually the distal lower extremity. *Courtesy Kalman Watsky, MD*.

eFig. 106.6 Spider telangiectasia. A Central arteriole with radiating telangiectatic "legs" on the cheek of a young child. **B** Multiple lesions in a jaundiced patient with liver disease. *A, Courtesy Phillip Bekhor, MD; B, Courtesy Ronald P. Rapini, MD*.

eFig. 106.8 Generalized essential telangiectasia. The site of initial involvement is usually the distal lower extremities. Sheets of asymptomatic blanchable telangiectasias appear bilaterally and over time can become widespread. *Courtesy Jean L. Bolognia, MD*.

Downloaded for Anonymous User (n/a) at Egyptian Knowledge Bank from ClinicalKey.com by Elsevier on March 10, 2024. For personal use only. No other uses without permission. Copyright ©2024. Elsevier Inc. All rights reserved.

eFig. 106.9 Hereditary hemorrhagic telangiectasia (HHT). A–C Multiple telangiectasias of the hand. The telangiectasias actually represent small arteriovenous malformations. *Courtesy Irwin Braverman, MD.*

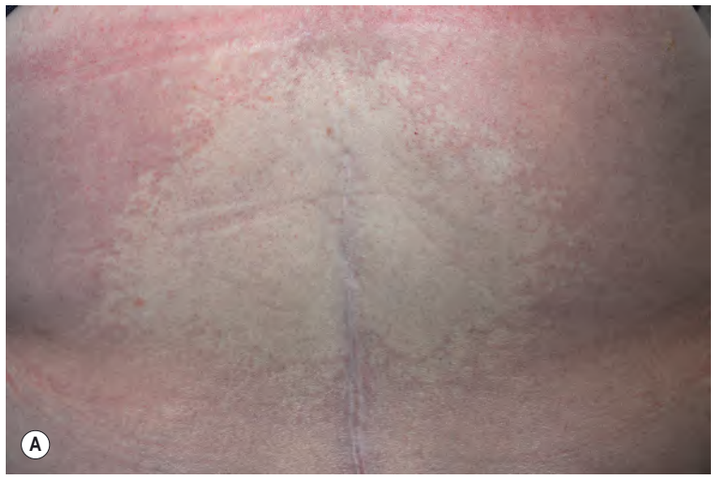

eFig. 106.10 Nevus anemicus. A Pale area of vasoconstriction with irregular borders on the back. **B** Obliteration of the border via application of pressure. *Courtesy Kalman Watsky, MD.*

Downloaded for Anonymous User (n/a) at Egyptian Knowledge Bank from ClinicalKey.com by Elsevier on March 10, 2024. For personal use only. No other uses without permission. Copyright ©2024. Elsevier Inc. All rights reserved.